Red Bucks Muchacha, “Barbie,” is the daughter of a three-time world champion roping horse. Owners Bob and Janie Kaser of Morris, Okla., brought the 2 year old filly back to Oklahoma State University’s Center for Veterinary Health Sciences for a follow up visit. Nearly one year ago, the horse was treated for a snake bite and medical complications that nearly cost the horse her life.

When Barbie first arrived at OSU’s Veterinary Teaching Hospital, her head and neck were swollen twice the size they normally would be. The horse had been bitten on the head between her eye and ear. Based on the location of the Kaser’s home, the attending veterinarians suspected a pigmy rattlesnake was the culprit.

After three days at the Veterinary Teaching Hospital, a very large swelling appeared on the left side of Barbie’s neck. According to Dr. Lyndi Gilliam, Equine Internal Medicine, rattlesnake venom causes extensive tissue necrosis and sloughing.

“We will probably never know what caused the massive tissue loss in her neck, but it’s all related to the snake bite,” explains Dr. Gilliam.

Veterinarians used maggot therapy on the massive wound to aid the healing process. After a five-week stay at the Center for Veterinary Health Sciences, Barbie returned home with the Kasers. However, she wasn’t out of danger yet.

Drs. Gilliam and Todd Holbrook, Equine Internal Medicine, are following Barbie's progress for possible heart complications. Dr. Gilliam is conducting research on snake bites in horses. Her project focuses on defining the cardiac toxicity of rattlesnake venom in horses. A month after her release, Barbie returned to the Veterinary Teaching Hospital for a check up.

Nearly a year later, the horse is being examined once again to determine if there are any lasting affects. Barbie now weighs 1,128 pounds and her heart rate is normal at 44 beats per minute. Dr. Holbrook uses a sonogram to examine the horse's heart for any arrhythmias.

"There are specific toxins in the snake venom that could affect the heart," says Dr. Holbrook. "However, not all horses are affected that particular way by snake bites. Today, the ultrasound exam and an ECG did not reveal any abnormalities with Barbie's heart."

According to Janie, they will begin training the 2-year-old filly now that Barbie has a clean bill of health.

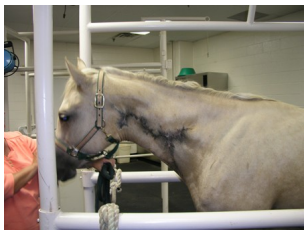

"We hope to use her for reining or a working cow horse. Her father is a three-time world champion roping horse," smiles Janie. "We took her to Shawnee for a show. She placed 6th out of 25 in her halter class. We were very pleased. I am amazed at her recovery every time I look at the pictures. We are forever grateful for the care Barbie continues to receive here at the Veterinary Center."

Click the following link to watch the News Report.
Daughter of Champion Horse Survives Snake Bite and Medical Complications